



PATIENT

Trixie Kadziauskas

SPECIES

Canine

BREED

Papillon Mix

SEX

Spayed Female

AGE

8

WEIGHT

21.8

INTERPRETED BY

Eric Lindquist, DMV,
DABVP (CFM), Cert.
IVUSS

IMAGING PERFORMED BY

Dr. Jenn Coop

HOSPITAL NAME

Westside AH

REFERRING VET

Dr. Jenn Coop

INVOICE

36216

DATE

3/14/26

PRESENTING CLINICAL SIGNS

- Month long history of PU/PD, increased appetite, weight gain, lethargy. Over the last few days, seems to be restless, can't get comfortable. eating/drinking fine, no vomiting/diarrhea. No previously hx labs.
- Abnormal PE/Chem/CBC/UA Results: Patient is obese. Moderate dental disease. H/L- WNL. Abdomen difficult to palpate due to BCS but suspect cranial organomegaly; panting. Couldn't completely r/o neck/back pain so trialed course of gabapentin. No improvements so owners came back for AUS. CBC- Stress leukogram w. mild thrombocytosis Chem- K+ 6.5, Cl 129, ALT 500, ALP > 2000, GGT 53, Chol 408 r/o primary GB disease/discomfort (unlikely w. GI signs) vs Cushings. Performed AUS for review- next steps pending review- LDDS. Monitor lesion in liver. Started Amoxi/Clav just in case due to gall bladder sludge/cholngi hep.

ULTRASONOGRAPHIC EXAMINATION OF THE ABDOMEN

Urinary System

The **urinary bladder**, trigone, and pelvic urethra presented normal thicknesses and normal tone. The ureters were not visible which is normal. No uroliths or sediment were visualized and anechoic urine was present. No evidence of inflammatory or neoplastic changes were noted. Ureteral papillae were normal. The pelvic urethra was imaged 1.0 cm beyond the cystourethral junction.

The **kidneys** revealed normal size and structure, corticomedullary definition and ratio for this age. The cortices presented largely uniform texture with normal echogenic relationship to liver and spleen. Medullary structure differed distinctly from the cortex, and no evidence of pelvic dilation was present. The capsules were acceptably uniform without significant irregularities. The left kidney measured 5.2 cm. The right kidney measured 5.2 cm.

Adrenal Glands

Both **adrenal glands** were slightly enlarged. The right adrenal gland measured 0.8 cm. The left adrenal gland measured 1.94 cm x 0.75 cm.

Spleen

The **spleen** was normal size and relatively normal contour with multifocal hyperechoic areas of mineralization. This is a benign change; however, can be related to Cushing's disease or other endocrinopathies.

Liver

The **liver** was uniformly swollen. The liver presented coarse architecture with mildly increased portal markings and subtle, mixed echogenic changes. This is consistent with vacuolar hepatopathy and some level of remodeling and history of inflammatory component. There was no overt suspicion of neoplasia. This is a mild change. A hypoechoic nodule was noted in the right cranial liver, adjacent to the gallbladder, measuring 1.0 cm. The **gallbladder** was mildly over distended with suspended and dependent debris, yet not to the level of emerging mucocele, yet sludge appears to be mildly excessive. No adjunctive inflammation was noted. Small calculi were also noted in the neck of the gallbladder.



PATIENT

Trixie Kadziauskas

SPECIES

Canine

BREED

Papillon Mix

SEX

Spayed Female

AGE

8

WEIGHT

21.8

INTERPRETED BY

Eric Lindquist, DMV,
DABVP (CFM), Cert.
IVUSS

IMAGING PERFORMED BY

Dr. Jenn Coop

HOSPITAL NAME

Westside AH

REFERRING VET

Dr. Jenn Coop

INVOICE

36216

DATE

3/14/26

Gastrointestinal

Examination of the **gastrointestinal tract** revealed a stomach and intestine free of stasis, of normal wall thickness, acceptable curvilinear mural detail, and peristaltic activity. Small and large intestine demonstrated normal luminal chyme and stool consistency respectively. No obstructive or overt infiltrative disease was noted. No associated abnormal lymphatic activity was noted.

Pancreas

The base and limbs of the **pancreas** were observed to be largely isoechoic to surrounding omental fat. Pancreatic duct and capsular contour were acceptably normal and parenchyma respected normal curvilinear patterns. No overt evidence of active inflammatory or neoplastic disease was noted.

ULTRASONOGRAPHIC FINDINGS

- Prominent adrenal glands, PDH type presentation
- Subjectively benign hepatopathy with occasional nodular hyperplasia pattern
- Minor excessive gallbladder sludge and small calculi in the neck of the gallbladder
- Splenic mineralization

INTERPRETATION OF THE FINDINGS & FURTHER RECOMMENDATIONS

If urine specific gravity is < 1.020 , and the patient appears cushingoid, then work up for PDH is indicated. FNA of the liver could be considered as well. Periodic passage of biliary calculi may be an issue in this patient; however, the common bile duct was normal and non-obstructed. Ursodiol therapy is indicated over a 6-8 week period and recheck sonogram of the right liver nodule and gallbladder. The right cranial liver nodule may be difficult to access with FNA, but ideally, if growing, especially FNA would be appropriate.

Cushing Work UP

Efficient & Accurate Cushing's Work up-Lindquist

Notes regarding Cushing's Clinical Presentations:

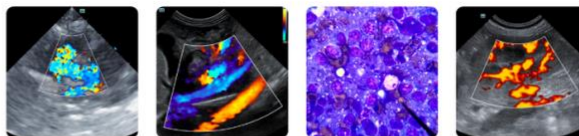
Nearly all Cushing's dogs have SAP elevations and true PU/PD (USG < 1.025) and most are polyphagic. Cushing's dogs are > 6 years and usually > 9 years old, usually have poor skin coats, body scores $> 3/5$, and are usually sedentary animals.

Its important to remember that Cushing's dogs usually look and play the part and other diseases cause false + stress related cortisol spikes. On rare occasion a Cushing's dog will not follow the rules but this is truly an exception.

Potential Cushing's patient workups can be costly and frustrating if not definitive and, in my experience, the non-definitive patient usually has something else going on that may be contributing to some of the clinical signs a Cushing's dog will have, especially SAP elevations or PU/PD. Based on this prelude of information I came up with the following algorithm in the spirit of diagnostic efficiency.

The following suggested protocol is based on current available literature on Cushing's disease and extensive clinical-sonographic experience evaluation + Cushing's and False + LDDST & ACTH stim. cases in order to maximize the efficiency of a Cushing's workup in practice.

Screen first, workup second



PATIENT

Trixie Kadziauskas

SPECIES

Canine

BREED

Papillon Mix

SEX

Spayed Female

AGE

8

WEIGHT

21.8

INTERPRETED BY

Eric Lindquist, DMV,
DABVP (CFM), Cert.
IVUSS

IMAGING PERFORMED BY

Dr. Jenn Coop

HOSPITAL NAME

Westside AH

REFERRING VET

Dr. Jenn Coop

INVOICE

36216

DATE

3/14/26

1) **UA:** Repeatable (2-3 urine samples) Urine specific gravity & urine cortisol/creatinine ratio (UCCR): If **repeatable USG < 10.20 and + UCCR** move to next step 2.

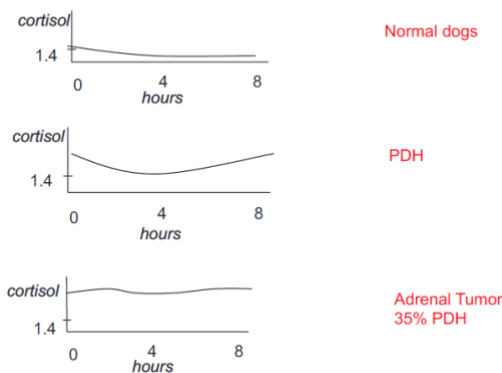
Note: UA is inexpensive and easy to obtain and if UA criteria is not met for Cushing's then resources can be spent into other more pertinent diagnostics or left on hold until the UA criteria is met in emerging Cushing's cases.

2) **Sonogram:** Does the patient **have concurrent disease** clinically or sonographically as non-Cushing's illness will influence the potential false + LDDST or even ACTH stim. The sonogram gives a global perspective of the internal health of the patient to be considered in the Cushing's workup as an assessment of concurrent disease. Is there a concurrent neoplastic process, UTI pancreatitis, mucocele...? Are the adrenals enlarged (Cushing's-PDH, stress, age related or breed variant), or atrophied (iatrogenic Cushing's or adrenal burnout), have asymmetric enlargement (Adrenal tumor, hyperplasia, adenoma, age related variant), or is there vascular invasion (Invasive pheo with false + UA criteria or adenocarcinoma or phrenic thrombosis)? The sonogram answers these questions proactively.

Address & treat concurrent disease first before performing Cushing's testing or testing will be artificially altered increasing false negatives and positives.

3) **LDDST** (0.01 D-Sodium phosphate mg/kg IV **with precise dosing******) (Better screening test but plagued with false + but considered more specific than ACTH stim) Use if there is potential early Cushing's or if adrenal asymmetry present on sonogram suspecting tumor. Use LDDST in cats at a higher dose (0.1 mg/kg IV). **Interpretation LDDST:** Look at 8-hour post first: If > 1.4 = Cushing's. Then look at 4-hour: if > 1.4 or > 50% baseline = Cushing's. 4-hour do then 8-hour spike most consistent with PDH. Flat line high constant curve without dip more consistent with tumor but can be PDH. See attached graph.

LDDS



Courtesy: Rebecca Berg DACVIM, DECVIM

4) **ACTH stim.** (Better confirming test but can have false +) Use if the patient "looks" Cushingoid or if bilateral adrenal enlargement is present, or high normal width on sonogram, or if iatrogenic Cushing's suspected (Cortisone Tx in past). ACTH stim is better for diagnosis of Addison's, iatrogenic Cushing's,



PATIENT

Trixie Kadziauskas

SPECIES

Canine

BREED

Papillon Mix

SEX

Spayed Female

AGE

8

WEIGHT

21.8

INTERPRETED BY

Eric Lindquist, DMV,
DABVP (CFM), Cert.
IVUS

IMAGING PERFORMED BY

Dr. Jenn Coop

HOSPITAL NAME

Westside AH

REFERRING VET

Dr. Jenn Coop

INVOICE

36216

DATE

3/14/26

and Cushing's therapy monitoring but problematic with initial Cushing's diagnosis. First dx LDDST is suggested.

5) If **diabetic** then run both LDDST & ACTH stim but stabilize as much as possible first.

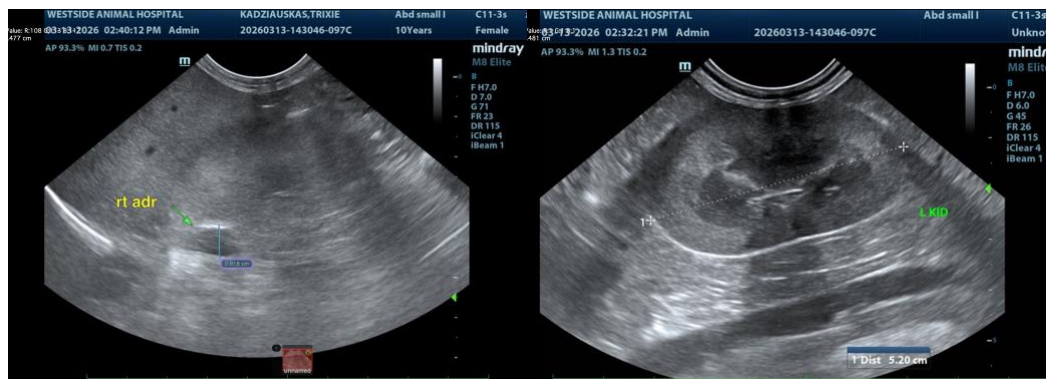
5) Run a **serial blood pressure** in a BP friendly non "white coat effect" atmosphere. Run at least 3 at different times over a few hours or when eating as the patient tends to be calm when eating or give Torbutrol when entering the facility. Cushing's hypertension is usually 150-180 systolic range while pheochromocytoma range is more often > 180 systolic.

6) **Perform CT** of the pituitary to identify macro adenoma expansion if any lethargy or dullness or other central clinical CNS signs are minimally present. CT for adrenal may be more thorough for adrenalectomy surgical planning if ultrasound views of the CVC were problematic.

7) **Adrenalectomy** for adrenal mass is prescribed then it is essential to stabilize the patient first regarding secondary disease such as organ dysfunction, hypertension, diabetes mellitus, hypernatremia, thromboembolic risk urinary and other infection in order to minimize potential for operative and postoperative complications as they are common in adrenalectomy. Trilostane stabilization therapy for Cushing's would be the first approach then address surgery and hypertension should be managed ideally < 160 systolic with ace inhibitors, phenoxybenzamine, or amlodipine.

Suggested reading:

Behrend EN, Kooistra HS, Nelson R, et al. Diagnosis of Spontaneous Canine Hyperadrenocorticism: 2012 ACVIM Consensus Statement (Small Animal). J Vet Intern Med 2013;27:1292-1304 .





PATIENT

Trixie Kadziauskas

SPECIES

Canine

BREED

Papillon Mix

SEX

Spayed Female

AGE

8

WEIGHT

21.8

INTERPRETED BY

Eric Lindquist, DMV,
DABVP (CFM), Cert. IVUSS

IMAGING PERFORMED BY

Dr. Jenn Coop

HOSPITAL NAME

Westside AH

REFERRING VET

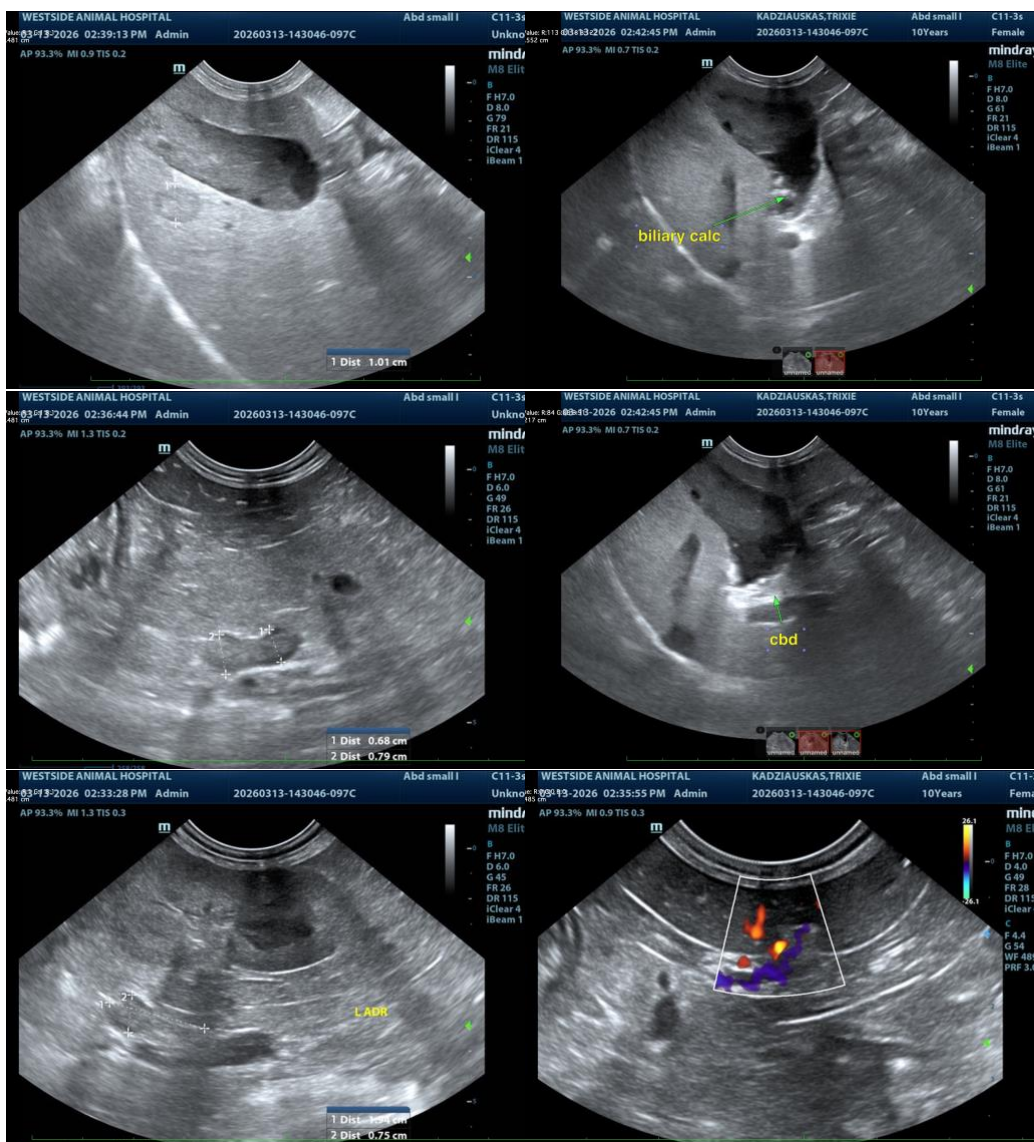
Dr. Jenn Coop

INVOICE

36216

DATE

3/14/26



The information and recommendations provided are based on the images presented by the referring veterinarian/sonographer. No evaluation can be communicated regarding pathology that was not visible in the image/video clips provided.

Thank you for this referral. If the clinical or image interpretation does not parallel your findings or if I can be of any further assistance please contact me.

Eric Lindquist, DMV, DABVP(CFM), Cert. IVUSS,
CEO, Owner, Founder -- SonoPath.com
info@SonoPath.com